

Nailfold videocapillaroscopic patterns and serum autoantibodies in systemic sclerosis

M. Cutolo, C. Pizzorni, M. Tuccio, A. Burrioni, C. Craviotto, M. Basso¹,
B. Seriola and A. Sulli

Background. Microvascular lesions are a predominant feature in systemic sclerosis (SSc) and seem to play a central pathogenetic role. Recently, we graded scleroderma microangiopathy by nailfold videocapillaroscopy (NVC) into three NVC patterns (early, active and late). The aim of the present study was to confirm, in a larger number of SSc patients, the presence of three patterns of microvascular damage, and to detect any possible relationship between these patterns and both specific serum autoantibodies and the subsets of cutaneous involvement.

Methods. Two hundred and forty-one consecutive patients (227 women and 14 men) affected by SSc were recruited. One hundred and forty-eight patients were affected by limited cutaneous SSc (lSSc) and 93 patients by diffuse cutaneous SSc (dSSc). The ages at onset of Raynaud's phenomenon (RP) and SSc, the durations of RP and SSc, ANA and antitopoisomerase I (anti-Scl70) and anticentromere (ACA) antibodies were investigated in all patients. The SSc patients were subdivided on the basis of the NVC pattern into three groups.

Results. A statistically significant correlation was found between the NVC patterns and the durations of both RP and SSc ($P < 0.001$). Enlarged and giant capillaries, together with haemorrhages, constituted the earliest NVC finding in SSc (early NVC pattern). These abnormalities were mostly expressed in the active NVC pattern. Loss of capillaries, ramified capillaries and vascular architectural disorganization were increased in the late NVC pattern. Age and the duration of both RP and SSc were lower in 24 patients complaining of RP alone. Anti-Scl70 antibodies were statistically less frequent in the early vs both the active and the late NVC pattern, whereas no significant correlation was found between the presence of anti-Scl70 antibodies and the duration of either RP or SSc. ACA positivity was more frequent in patients with longer RP duration. Patients with lSSc had shorter SSc duration and showed the early or active NVC pattern more frequently. Conversely, patients with dSSc showed longer disease duration and mostly showed the late NVC pattern.

Conclusions. NVC is an appropriate tool for differential diagnosis between primary and secondary RP through the clear recognition of the early NVC scleroderma pattern. This study confirms, in a large number of SSc patients, the existence of three distinct NVC patterns that might reflect the evolution of SSc microangiopathy. The presence of anti-Scl70 antibodies seems to be related to earlier expression of the active and late NVC patterns of SSc microvascular damage. The presence of ACA seems to be related to delayed expression of the late NVC pattern.

KEY WORDS: Systemic sclerosis, Capillaroscopy, Scleroderma pattern, Raynaud's phenomenon, Microangiopathy, Anticentromere antibodies, Antitopoisomerase antibodies.

Systemic sclerosis (SSc) is a connective tissue disease which affects various tissues and organs, including peripheral vessels, skin, lungs, kidneys, gastrointestinal tract and cardiovascular system.

The aetiology of SSc is not clear and is most likely multifactorial. However, it is currently believed that the disease may begin as an autoimmune response to an unknown antigen [1–3]. In this regard, there is evidence that both humoral and cellular immunity may play roles [2, 3].

The pathophysiology of SSc is complex and consists of three major features: vascular damage, followed by mononuclear cell infiltration and massive deposition of newly synthesized connective tissue, mainly collagen [3, 4]. The mechanism of vascular damage is not well understood, but the interaction of immune cells with the vascular endothelium and an imbalance in the fibrinolytic system are strongly hypothesized [5–10].

Microvascular lesions are a predominant feature in SSc and seem to play a central pathogenetic role. Moreover, microangiopathy appears to be the best evaluable predictor of the development of SSc and seems to precede the other symptoms by many years [11]. Follow-up studies have already suggested that microvascular lesions might precede severe involvement of internal organs [11–14].

Peripheral microvascular damage in SSc is characterized by structural alterations of the capillaries with a progressive decrease in capillary density. Enlarged and giant capillaries, haemorrhages, disorganization of the vascular array and ramified/bushy capillaries are present [11, 15–19].

Early in the disease, peripheral microangiopathy may be well recognized and studied by nailfold capillaroscopy, a non-invasive and safe technique that is reported to have both diagnostic

Research Laboratory and Division of Rheumatology and ¹Division of Immunology and Internal Medicine, Department of Internal Medicine, University of Genova, Genova, Italy.

Submitted 1 August 2003; revised version accepted 14 January 2004.

Correspondence to: M. Cutolo, Research Laboratory and Division of Rheumatology, Department of Internal Medicine, University of Genova, Viale Benedetto XV, no. 6, 16132 Genova, Italy. E-mail: mcutolo@unige.it

and prognostic value also in the presence of isolated Raynaud's phenomenon (RP) [17, 20–24].

A limited number of studies have described the morphological aspects of vascular damage in patients with SSc by nailfold capillaroscopy, relating these capillary abnormalities to selected characteristics of the disease [11, 18, 19, 23, 25].

Recently, we graded by nailfold videocapillaroscopy (NVC) the scleroderma microangiopathy into three NVC patterns (early, active and late) that were found to correlate with the duration of both RP and SSc and reflected at least the evolution of the disease process [26].

The aim of the present study was to confirm, in a larger number of SSc patients, the presence of the three patterns of microangiopathy and to investigate any possible relationship between these patterns and both specific serum autoantibody patterns and the subsets of cutaneous involvement.

Patients and methods

Patients

Two hundred and forty-one consecutive patients [227 women (mean age 57 ± 15 yr) and 14 men (mean age 56 ± 18 yr)], affected by SSc according to the American College of Rheumatology criteria [27, 28], were recruited from our videocapillaroscopy service for the diagnosis of vascular and connective tissue diseases during the period from 1998 to 2002.

One hundred forty-eight patients (61%) (mean age 58 ± 15 yr) were found to be affected by limited cutaneous SSc (lSSc) (skin involvement of the fingers, hands, forearms, toes, feet, legs, neck and face) and 93 (39%) (mean age 56 ± 15 yr) showed diffuse cutaneous SSc (dSSc) (skin involvement of arms, thighs, chest, abdomen and back), according to the guidelines of LeRoy *et al.* [28, 29]. All patients referred the presence of RP.

In twenty-four patients (10%) who complained of RP alone and who were not positive for serum antinuclear antibodies (mean age 50 ± 16 yr), the early diagnosis of SSc was initially suggested as result of the NVC analysis and was subsequently confirmed by other instrumental evaluations. Asymptomatic oesophageal and/or lung involvement was present in this subgroup of patients, as was mild sclerodactyly. These patients were considered to have limited scleroderma and met at least two minor ARA criteria.

The age at onset of RP and SSc and the duration of RP and SSc were investigated in all patients. The durations of RP and SSc at the time of NVC assessment were evaluated by clinical interview and from clinical file data. In particular, the duration of SSc was calculated from the time of onset of clinical signs or symptoms (different from RP) clearly related to SSc (i.e. skin fibrosis, dysphagia, etc.) or from the time of instrumental and/or laboratory investigations confirming the diagnosis (i.e. NVC, oesophageal and/or pulmonary involvement, detection of serum autoantibodies).

No patients had been treated previously with D-penicillamine, prostanoids, immunosuppressive agents (patients treated in the past with the above-mentioned drugs were excluded from the study). Patients were treated, when required, with vasodilators (bufomedil), antihypertensive drugs (diuretics or calcium channel blockers), NSAIDs, and no more than 5 mg/day prednisone equivalent. No systemic diseases other than SSc were concomitant.

Informed consent was obtained from all patients before entry to the study.

Autoantibody detection

Total ANA, antitopoisomerase I (anti-Scl70) antibodies and anticentromere antibodies (ACA) were sought in all patients. ANA were detected by indirect immunofluorescence using HEP-2

cells as substrate (Euroimmun). Anti-Scl70 antibodies and ACA were evaluated using an ELISA (Euroimmun). Values were expressed as positive or negative. The ANA titre was not recorded.

Nailfold videocapillaroscopy

NVC was performed by using an optical probe videocapillaroscopy equipped with 100 \times and 200 \times contact lenses and connected to image analyse software (Videocap; DS MediGroup, Milan, Italy). Images (pixel dimensions 762 horizontal \times 582 vertical) were also observed on a high-resolution colour monitor (14 inches) and printed on a digital PAL video printer (print format 84.5 \times 110 mm, 256 colours; Hitachi, Japan).

The same operator, without knowledge of the patient's clinical diagnosis and/or disease severity, performed the NVC examination in a blind manner.

Each subject was inside the building for a minimum of 15 min before the nailfold was examined and the room temperature was 20–22°C. The nailfolds of all 10 fingers were examined in each patient, after a drop of immersion oil had been placed on the nailfold bed to improve the image resolution. Fingers affected by recent local trauma were not analysed.

The following parameters were considered, according to previous classifications: presence of enlarged and giant capillaries, haemorrhages, loss of capillaries, disorganization of the vascular array, and ramified/bushy capillaries [11, 17–19, 26].

On the basis of the NVC abnormalities, the SSc patients were distributed into the appropriate NVC pattern, as previously reported [26]. The patterns included: (i) early pattern: few (fewer than four altered capillaries per millimetre) enlarged/giant capillaries, few capillary haemorrhages, relatively well-preserved capillary distribution, no evident loss of capillaries; (ii) active pattern: frequent (more than six altered capillaries per millimetre) giant capillaries, frequent capillary haemorrhages, moderate (20–30%) loss of capillaries, mild (between four and six altered capillaries per millimetre) disorganization of the capillary architecture, absent or mild ramified capillaries; and (iii) late pattern: irregular enlargement of the capillaries, few or absent giant capillaries and haemorrhages, severe (50–70%) loss of capillaries with large avascular areas, disorganization of the normal capillary array and ramified/bushy capillaries (Fig. 1).

A semiquantitative rating scale to score these changes was adopted, according to previous studies (0 = no changes; 1 = fewer than four alterations; 2 = four to six alterations; 3 = more than six alterations per millimetre) [11, 26]. For each subject, the mean score for each of these parameters was obtained from the analysis of the second, third, fourth and fifth fingers of both hands, using the scoring system described above.

Subsequently, in each group, the clinical characteristics of the patients (age, age of onset of RP and SSc, duration of RP and SSc), the presence of ANA, anti-Scl70 antibodies, ACA, and the expression of the lSSc or dSSc subset of the disease were evaluated and correlated with the NVC patterns.

Statistical analysis

The statistical analysis was performed by analysis of variance (ANOVA), the non-parametric Kruskal–Wallis and Mann–Whitney *U* tests for discontinuous data, logistic regression and the χ^2 test. $P < 0.05$ was considered statistically significant.

Results

The early NVC pattern was observed in eighty patients (33%), the active NVC pattern in 90 patients (37%) and the late NVC pattern in 71 patients (29%). Mean ages of patients, ages at onset of RP and

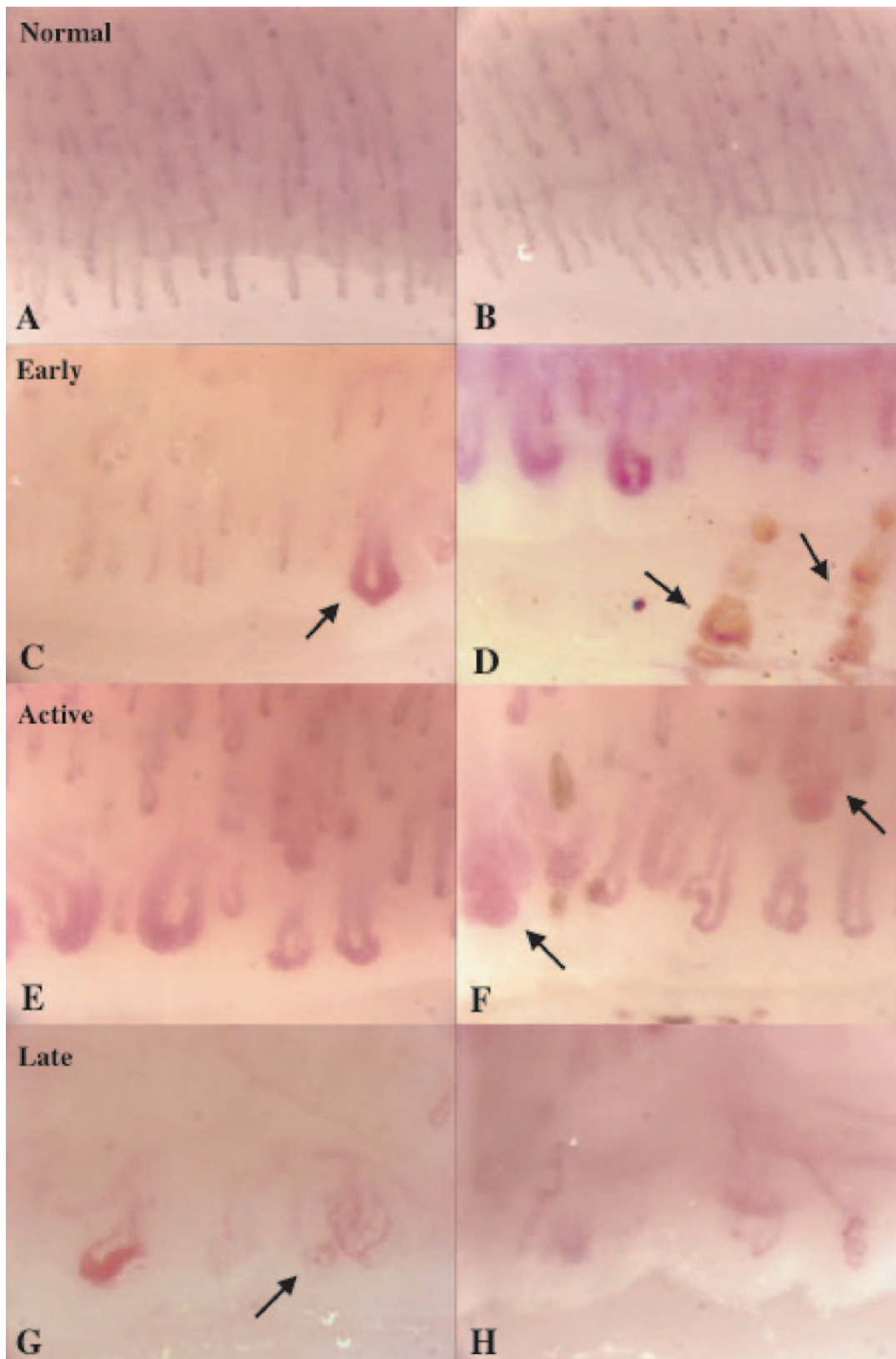


FIG. 1. Representation of the normal NVC pattern (A, B) and the three nailfold videocapillaroscopy scleroderma patterns (C and D, E and F, G and H). The early pattern (C, D) is characterized by well-preserved capillary architecture and density, the presence of enlarged capillaries, giant capillaries (C, arrow) and haemorrhages (D, arrows). The active pattern (E, F) is characterized by frequent giant capillaries and haemorrhages, moderate loss of capillaries and disorganization of capillary architecture, with rare ramified capillaries (F, arrow). The late pattern (G, H) is characterized by severe capillary architecture disorganization with loss of capillaries, the presence of ramified capillaries (G, arrow), very few giant capillaries, absence of haemorrhages, and large avascular areas. Magnification 200 \times .

TABLE 1. Mean age of patients and age at onset and duration of RP and SSc in each NVC pattern

NVC pattern	Age of patients (yr)	RP Duration (yr)	SSc duration (yr)	Age of onset of RP (yr)	Age of onset of SSc (yr)
Early (80 patients)	53 ± 16	11 ± 12	2 ± 4	40 ± 17	49 ± 15
Active (90 patients)	58 ± 13	12 ± 10	5 ± 5	47 ± 15	53 ± 13
Late (71 patients)	61 ± 15	18 ± 12	10 ± 8	43 ± 16	50 ± 15
Early vs active vs late (ANOVA factorial)	$P < 0.001$	$P < 0.001$	$P < 0.0001$	n.s.	n.s.

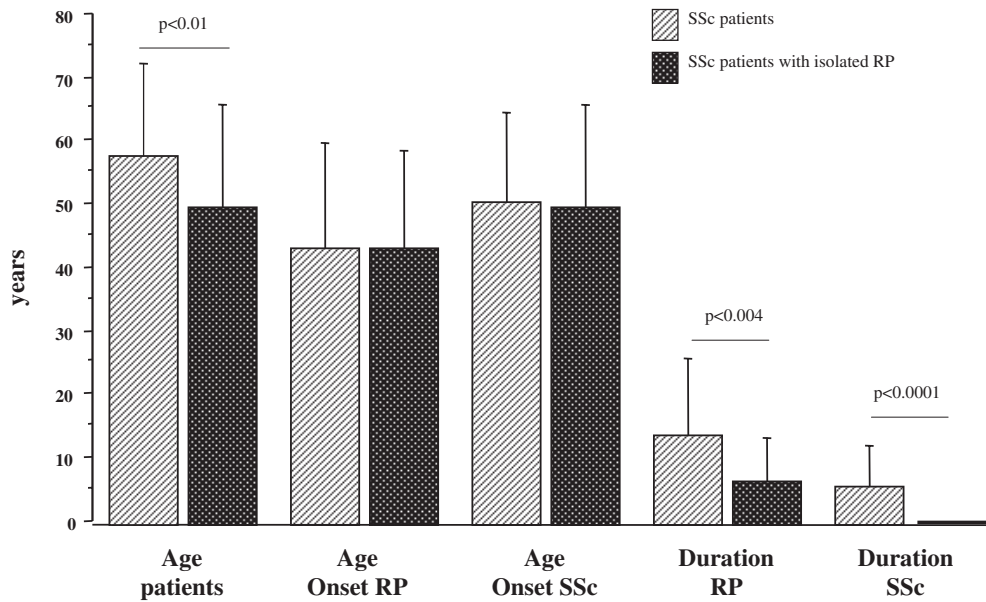


FIG. 2. Mean age of the patients, age of onset and duration of RP and SSc in SSc patients, compared with those of patients complaining of RP alone only.

SSc and the durations of RP and SSc, within each pattern, are reported in Table 1.

The durations of RP and SSc were significantly longer in patients showing the late NVC pattern compared with those with the active and early NVC patterns ($P < 0.001$ and $P < 0.0001$ respectively). The age of patients was higher in those showing the late NVC pattern compared with those showing the active and early NVC patterns ($P < 0.001$). No statistically significant difference was found among the three NVC patterns concerning the ages at onset of both RP and SSc (Table 1). Logistic regression analysis confirmed the relationship between the age of patients and the durations of RP and SSc.

The mean age and the durations of RP and SSc were lower in 24 patients complaining of RP alone (negative for autoantibodies, positive for SSc microvascular involvement) compared with those of the other SSc patients. Conversely, the ages at onset of RP and SSc were similar in the two groups of patients (Fig. 2).

Giant capillaries and haemorrhages were more frequent in the active NVC pattern compared with the early and late NVC patterns (Fig. 3A). Loss of capillaries, disorganization of the vascular array and ramified capillaries were observed more frequently in the late than in the active and early NVC patterns, and in the active than in the early NVC pattern (Fig. 3B).

No statistically significant difference was found between the early, active and late NVC patterns concerning the frequency of ANA positivity. However, ANA were detected in 84, 93 and 94% of SSc patients with the early, active and late NVC patterns respectively (total, 90% of SSc patients) (Fig. 4).

Patients who were positive for ANA had significantly longer durations of RP and SSc than ANA-negative SSc patients ($P < 0.03$).

Anti-Scl70 antibodies were positive in 5, 25 and 24% of SSc patients with the early, active and late NVC pattern respectively (total, 19% of SSc patients). In particular, anti-Scl70 positivity was statistically lower in the early pattern than in the active pattern, and in the early vs the late NVC patterns ($P < 0.01$) (Fig. 4). No statistically significant correlations were observed between anti-Scl70 positivity and RP or SSc duration.

ACA were detected in 49, 46 and 41% of SSc patients with the early, active and late NVC pattern respectively (total, 46% of SSc patients) (Fig. 4). No statistically significant difference was found between the three patterns concerning the presence of ACA ($P = 0.07$). On the contrary, a statistically significant correlation was observed between the presence of ACA and the durations of both RP and SSc ($P < 0.03$).

Patients with the early or active NVC pattern showed ISSc more frequently than patients with the late NVC pattern; the latter, on the contrary, were more often affected by the dSSc ($P < 0.001$). In particular, 74, 66 and 43% of patients with the early, active and late NVC pattern, respectively, were affected by ISSc (Fig. 5).

In addition, patients affected by dSSc showed longer disease duration than those affected by ISSc ($P < 0.001$). No statistically significant difference was found between ISSc and the dSSc concerning the duration of RP, age, the age at onset of either RP or SSc, or the presence of autoantibodies (Table 2). ANA were found in 89 and 94% of patients with ISSc and with dSSc respectively. Anti-Scl70 antibodies were found in 15 and 25% of patients with ISSc and dSSc respectively ($P = 0.09$), and ACA in 52 and 37% of patients with ISSc and dSSc respectively ($P = 0.06$) (Table 2).

No statistically significant difference was found between male and female patients concerning the age at onset and duration of

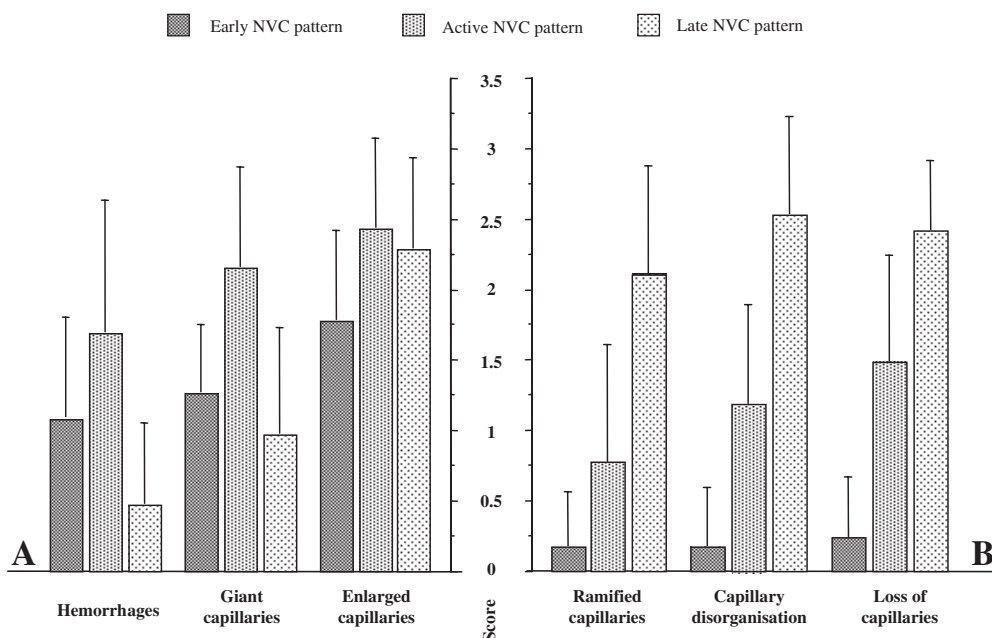


FIG. 3. Occurrence of the different NVC morphological parameters in the three pattern groups (total of 241 SSc patients). Enlarged and giant capillaries and haemorrhages represent the earliest NVC findings in SSc (early NVC pattern). These microvascular changes are strongly increased in SSc patients showing the active NVC pattern, whereas in the late NVC pattern these abnormalities are rare (A). Loss of capillaries together with both ramified capillaries and vascular architectural disorganization increase progressively in the three NVC patterns (early, active and late) (B). The error bars indicate the standard deviation.

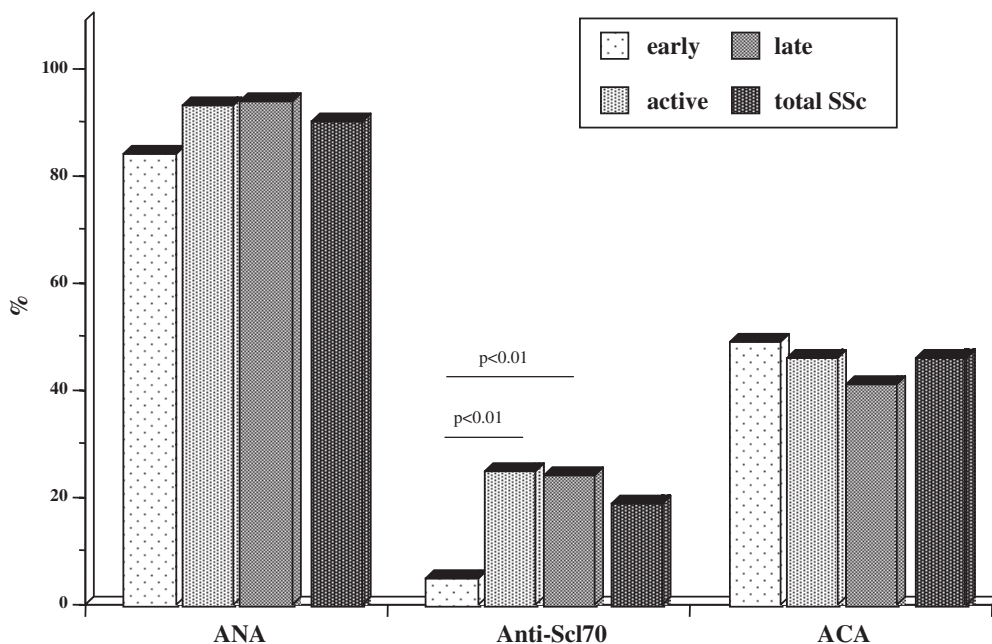


FIG. 4. Occurrence of ANA and antitopoisomerase (anti-Scl70) and anticentromere (ACA) antibodies within each NVC pattern (early, active and late) and in all 241 SSc patients.

RP and SSc, the frequency of NVC parameters in the different patterns, SSc skin involvement and the presence of autoantibodies.

Discussion

This study confirms in a large number of SSc patients the identification of distinct NVC patterns (early, active and late), as

assessed by NVC examination, that might correlate with some clinical and laboratory manifestations of scleroderma [26].

These three major patterns seem to reflect the evolution of SSc microangiopathy and their recognition might be useful in assessing microvascular damage in individual patients, both at a single point in time and longitudinally. The assumption that these patterns might reflect the evolution of SSc microangiopathy is based on the demonstration that SSc patients with the late NVC pattern have a longer disease duration than those with the active or early pattern.

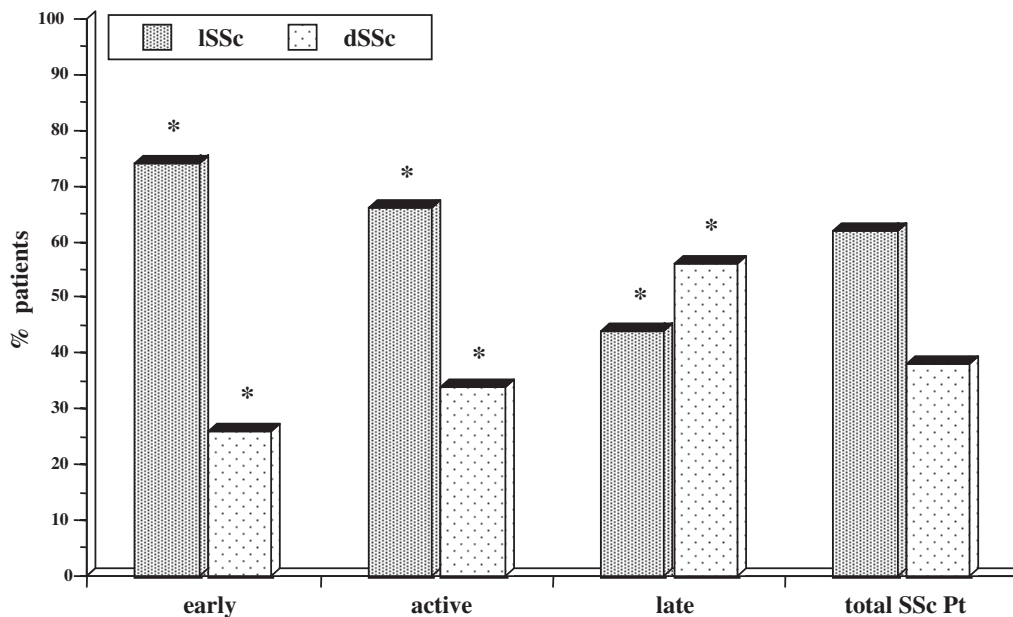


FIG. 5. Occurrence of both ISSc and dSSc within each NVC pattern (early, active and late) and in all 241 SSc patients. * $P < 0.001$, ISSc vs dSSc.

TABLE 2. Mean age of patients, age of onset and duration of RP and SSc, occurrence of ANA, anti-Scl70 antibodies and ACA in patients with ISSc and dSSc

	Age of patients (yr)	Age of onset of RP (yr)	Age of onset of SSc (yr)	RP duration (yr)	SSc duration (yr)	ANA positivity (%)	Anti-Scl70 positivity (%)	ACA positivity (%)
ISSc (148 patients)	58 ± 15	44 ± 17	52 ± 15	13 ± 11	4 ± 5	89	15	52
dSSc (93 patients)	56 ± 15	42 ± 15	48 ± 13	14 ± 12	7 ± 8	94	25	37
ISSc vs dSSc	n.s.	n.s.	n.s.	n.s.	$P < 0.001$	n.s.	n.s.	n.s.

We also followed some patients who developed an active or a late NVC pattern a few years after the diagnosis of an early or active pattern, respectively (data not shown). However, longitudinal studies are necessary to confirm this statement.

It seems unlikely that the relationship between disease duration and NVC pattern could be the result of the recruitment pattern of patients with scleroderma, as patients with ISSc are often recognized late and patients with dSSc are usually admitted early. In this study, we evaluated the duration of both SSc and RP. Even though ISSc might be identified later, we found a statistically significant correlation between NVC pattern and the duration of both SSc and RP.

Criteria to define disease activity or severity in SSc have been proposed by several authors [30, 31, 33]. Few reports have described the morphological aspects of SSc microangiopathy, as detected by capillaroscopy, and compared the capillary abnormalities with selected characteristics of the disease [11, 18, 19, 23, 25, 32, 34].

Patients with severe loss of capillaries have already been reported to have longer disease duration than those with limited capillary loss [35]. In the present study, loss of capillaries, ramified capillaries and vascular architectural disorganization were found to be rare in the early stages of SSc, whereas a progressive increase in these vascular abnormalities was observed in the active and late NVC patterns.

The appearance of enlarged and giant capillaries, together with haemorrhages, represents the earliest NVC finding in SSc (early NVC pattern) [11, 16, 26]. These microvascular changes were strongly increased in SSc patients showing the active NVC

pattern, whereas in the late NVC pattern these abnormalities appeared to be very rare. The presence of more than one giant capillary is usually pathognomonic for the scleroderma pattern of microangiopathy [17, 36].

However, selected vascular abnormalities observed by NVC in SSc patients (i.e. enlarged and ramified capillaries, haemorrhages, loss of blood vessels) may be seen in dermatomyositis (DM) and in other major connective tissue diseases, although with different expression [17, 37, 38].

Generally, RP is considered the first clinical sign of vascular involvement in SSc and may precede other symptoms by several years, while clinical visceral involvement tends to occur later in the course of the disease [39, 40]. Twenty-four out of 241 patients (10%) complained of RP alone. These patients were negative for the autoantibodies tested, whereas the NVC examination showed the presence of SSc microangiopathy, and other tools subsequently confirmed the diagnosis of SSc (i.e. oesophageal manometry, lung function tests). On the other hand, follow-up studies have already suggested that the microvascular lesions might precede severe involvement of the internal organs [11–14, 41]. In this subset of patients (RP alone), the mean age and duration of RP and SSc were lower than in the other SSc patients.

Therefore, NVC is an appropriate tool for the differential diagnosis between primary and secondary RP, through the clear recognition of the early NVC pattern [42].

The NVC scleroderma-like pattern may be observed in patients with DM, mixed connective tissue disease (MCTD) and, less frequently, SLE when an overlap syndrome is present [17, 37, 38]. Usually, patients affected by MCTD or DM have CRP and ERS

above the normal range and other clinical symptoms are present. Moreover, the capillaroscopic pattern of DM and MCTD is quite different from that of SSc: the microangiopathy is characterized by a higher number of ramified/bushy capillaries, which are already in the early stages of the disease. The patients enrolled in the study, with ISSc but without ANA, had normal laboratory examinations, the videocapillaroscopic pattern was not suspicious for other connective tissue disease, and after 2–4 yr of observation the diagnosis of SSc was not changed. Therefore, the possibility that this subset of patients might have other diagnoses (such as DM or SLE) is quite difficult to confirm or refute.

The pattern of microangiopathy may change in SSc patients with time, as may any specific capillary irregularity. Results of NVC examinations are always different in the same patient, even only a few months after the previous assessment (in healthy subjects the capillary loops and arrangement do not change with time, and the same picture is still present some years later). NVC abnormalities such as enlarged and giant capillaries are the first sign of SSc microangiopathy, but they become rare in patients with longer disease duration; on the contrary, capillary rarefaction and ramifications are rare in the early stage of SSc microangiopathy but are common in patients with longer SSc duration. What induces the evolution of the microvascular changes is unknown. The presence or absence of specific autoantibodies might influence the rate of evolution of microvascular damage. In our study, no statistically significant difference was found between the three NVC patterns concerning the presence of ANA. However, patients with longer disease duration were positive for ANA more frequently. The presence of anti-Scl70 antibodies was statistically more frequent in both the active and the late NVC pattern than in the early pattern, whereas no significant correlation was found between the presence of the anti-Scl70 antibodies and the duration of either RP or SSc. Therefore, the presence of anti-Scl70 antibodies seems to be an earlier event and might be related to earlier expression of the active and late NVC patterns of SSc microvascular damage. On the contrary, ACA were found more frequently in the early pattern and decreased in the other patterns. In addition, the presence of ACA was significantly more frequent in patients with longer RP duration. Therefore, the presence of ACA might be related to delayed expression of the late NVC pattern. However, the possibility that ACA might be related to capillaroscopic abnormalities, like those observed in the early or the active NVC pattern, has been suggested already by other authors [11, 43].

Longitudinal studies are necessary to better correlate the presence of ACA and anti-Scl70 antibodies with the evolution of SSc microvascular damage, as evaluated by NVC.

None of the patients was positive for both anti-Scl70 antibodies and ACA at the same time. Simultaneous expression of anti-Scl70 antibodies and ACA is not totally and mutually exclusive, but their coincidence has been reported to be rare (<1% of patients with SSc) [44]. The evaluation of other autoantibodies, such as extractable nuclear antigens (ENA), anti-RNA polymerase I and III, anti-endothelial cell and anti-desmosomal antibodies, was not performed in this study, but might be matter for future assessment and correlation with NVC patterns.

Patients affected by ISSc were characterized by shorter disease duration, and they showed the early or active NVC patterns more frequently. On the contrary, patients affected by dSSc showed longer disease duration and mostly the late NVC pattern. As suggested by many authors, specific SSc autoantibodies might influence and/or modulate the rate of progression of SSc vascular damage, including possible effects on the expression of limited or diffuse skin involvement [45–50]. In agreement with previous reports, in the present study anti-Scl70 antibodies were detected more frequently in patients with dSSc and ACA in patients with ISSc, although a statistically non-significant difference was found between the two patterns of skin involvement and the frequency of presence of the antibodies ($P = 0.06$).

As reported in Table 2, if only RP is considered, a similar duration was found in both ISSc and dSSc patients. The duration of SSc from the first clinical sign was higher in dSSc than in ISSc patients, unlike the situation for RP. However, as patients with ISSc are often recognized late and patients with dSSc are usually admitted early, it might be difficult to establish exactly the duration of the disease in the two groups of patients.

In conclusion, NVC is confirmed as a suitable tool for the early diagnosis of microvascular damage in SSc, through the recognition of the early NVC pattern. Furthermore, the identification of different NVC patterns might be useful both to assess and to follow microvascular involvement in SSc.

Specific autoantibodies (anti-Scl70 and ACA) do not seem directly linked to the expression of a singular NVC pattern. However, these autoantibodies seem related to the rate of progression of the SSc microvascular damage. At the same time, some correlations seem evident between the presence of the ISSc or the dSSc subsets and the expression of the three NVC patterns of SSc vascular involvement.

Long-term longitudinal studies are necessary to better correlate the NVC patterns and the serum markers with other clinical manifestations of the disease, as has already been done in part [7, 51–56].

The authors have declared no conflicts of interest.

References

- Herrick AL, Worthington J. Genetic epidemiology: systemic sclerosis. *Arthritis Res* 2002;4:165–8.
- Black CM. Systemic sclerosis 'state of the art' 1995. *Scand J Rheumatol* 1995;24:194–6.
- Sapadin AN, Esser AC, Fleischmajer R. Immunopathogenesis of scleroderma-evolving concepts. *Mt Sinai J Med* 2001;68:233–42.
- Denton CP, Abraham DJ. Transforming growth factor-beta and connective tissue growth factor: key cytokines in scleroderma pathogenesis. *Curr Opin Rheumatol* 2001;13:505–11.
- Renaudineau Y, Grunebaum E, Krause I *et al.* Anti-endothelial cell antibodies (AECA) in systemic sclerosis-increased sensitivity using different endothelial cell substrates and association with other autoantibodies. *Autoimmunity* 2001;33:171–9.
- Andersen GN, Mincheva-Nilsson L, Kazam E *et al.* Assessment of vascular function in systemic sclerosis: indications of the development of nitrate tolerance as a result of enhanced endothelial nitric oxide production. *Arthritis Rheum* 2002;46:1324–32.
- Fatini C, Gensini F, Sticchi E *et al.* High prevalence of polymorphisms of angiotensin-converting enzyme (I/D) and endothelial nitric oxide synthase (Glu298Asp) in patients with systemic sclerosis. *Am J Med* 2002;112:540–4.
- Pearson JD. The endothelium: its role in scleroderma. *Ann Rheum Dis* 1996;50:633–8.
- Black CM. The aetiopathogenesis of systemic sclerosis. *J Intern Med* 1993;234:3–8.
- Della Bella S, Molteni M, Mocellin C, Fumagalli S, Bonara P, Scorza R. Lymphocyte-endothelium interaction in systemic sclerosis and Raynaud's phenomenon. *Clin Exp Rheumatol* 2001;19:647–54.
- Mariq HR, Harper FE, Khan MM, Tan EM, LeRoy EC. Microvascular abnormalities as possible predictors of disease subset in Raynaud's phenomenon and early connective tissue disease. *Clin Exp Rheumatol* 1983;1:195–205.
- Fitzgerald O, Hess EV, O'Connor GT, Spencer-Green G. Prospective study of the evolution of Raynaud's phenomenon. *Am J Med* 1988;84:718–26.
- Priollet P, Vayssairat M, Housset E. How to classify Raynaud's phenomenon. Long-term follow-up study of 73 cases. *Am J Med* 1987;83:494–8.

14. Gerbracht DD, Steen VD, Ziegler GL, Medsger TA, Rodnan GP. Evolution of primary Raynaud's phenomenon (Raynaud's disease) to connective tissue disease. *Arthritis Rheum* 1985;28:87-92.
15. Blann AD, Ilinworth K, Jayson MIV. Mechanisms of endothelial damage in systemic sclerosis and Raynaud's phenomenon. *J Rheumatol* 1993;20:1325-30.
16. Carpentier PH, Maricq HR. Microvasculature in systemic sclerosis. *Rheum Dis Clin North Am* 1990;16:75-91.
17. Blockmans D, Beyens G, Verhaeghe R. Predictive value of nailfold capillaroscopy in the diagnosis of connective tissue disease. *Clin Rheumatol* 1996;15:148-53.
18. Maricq HR. Widefield capillary microscopy: technique and rating scale for abnormalities seen in scleroderma and related disorders. *Arthritis Rheum* 1981;24:1159-65.
19. Kabasakal Y, Elvins DM, Ring EFJ, McHugh NJ. Quantitative nailfold capillaroscopy findings in a population with connective tissue disease and in normal healthy controls. *Ann Rheum Dis* 1996;55:507-12.
20. Von Bierbrauer AF, Mennel HD, Schmidt JA, Von Wichert P. Intravital microscopy and capillaroscopically guided nailfold biopsy in scleroderma. *Ann Rheum Dis* 1996;55:305-10.
21. Chandran G, Smith M, Ahern MJ, Roberts-Thomson PJ. A study of scleroderma in South Australia: prevalence, subset characteristics and nailfold capillaroscopy. *Aust NZ J Med* 1995;25:688-94.
22. Mannarino E, Pasqualini L, Fedeli F, Scricciolo V, Innocente S. Nailfold capillaroscopy in the screening and diagnosis of Raynaud's phenomenon. *Angiology* 1994;45:37-42.
23. Maricq HR, Le Roy EC, D'Angelo WA *et al.* Diagnostic potential of *in vivo* capillary microscopy in scleroderma and related disorders. *Arthritis Rheum* 1980;23:183-9.
24. LeRoy EC, Medsger TA Jr. Criteria for the classification of early systemic sclerosis. *J Rheumatol* 2001;28:1573-6.
25. Andrade LEC, Gabriel A Jr, Assad RL, Ferrari AJL, Atra E. Panoramic nailfold capillaroscopy: a new reading method and normal range. *Semin Arthritis Rheum* 1990;20:21-31.
26. Cutolo M, Sulli A, Pizzorni C, Accardo S. Nailfold videocapillaroscopy assessment of microvascular damage in systemic sclerosis. *J Rheumatol* 2000;27:155-60.
27. Masi AT, Medsger TA, Rodnan GP *et al.* Preliminary criteria for the classification of systemic sclerosis (scleroderma). *Arthritis Rheum* 1980;23:581-90.
28. LeRoy EC, Medsger TA Jr. Criteria for the classification of early systemic sclerosis. *J Rheumatol* 2001;28:1573-6.
29. LeRoy EC, Black CM, Fleischmajer R *et al.* Scleroderma (systemic sclerosis): classification, subsets and pathogenesis. *J Rheumatol* 1988;15:202-5.
30. Valentini G, Della Rossa A, Bombardieri S *et al.* European multicentre study to define disease activity criteria for systemic sclerosis. II. Identification of disease activity variables and development of preliminary activity indexes. *Ann Rheum Dis* 2001;60:592-8.
31. Medsger TA Jr, Silman AJ, Steen VD *et al.* A disease severity scale for systemic sclerosis: development and testing. *J Rheumatol* 1999;26:2159-67.
32. Bukhari M, Hollis S, Moore T, Jayson MI, Herrick AL. Quantitation of microcirculatory abnormalities in patients with primary Raynaud's phenomenon and systemic sclerosis by video capillaroscopy. *Rheumatology* 2000;39:506-12.
33. Merkel PA, Herlyn K, Martin RW *et al.* Measuring disease activity and functional status in patients with scleroderma and Raynaud's phenomenon. *Arthritis Rheum* 2002;46:2410-20.
34. Anders HJ, Sigl T, Schattenkirchner M. Differentiation between primary and secondary Raynaud's phenomenon: a prospective study comparing nailfold capillaroscopy using an ophthalmoscope or stereomicroscope. *Ann Rheum Dis* 2001;60:407-9.
35. Lovy M, MacCarter D, Steigerwald JC. Relationship between nailfold capillary abnormalities and organ involvement in systemic sclerosis. *Arthritis Rheum* 1985;28:496-501.
36. Maricq HR, LeRoy EC. Progressive systemic sclerosis—disorders of the microcirculation. *Clin Rheum Dis* 1979;5:81-101.
37. Michoud E, Poensin D, Carpentier PH. Digitized nailfold capillaroscopy. *Vasa* 1994;23:35-42.
38. Furtado RN, Pucinelli ML, Cristo VV, Andrade LE, Sato EI. Scleroderma-like nailfold capillaroscopic abnormalities are associated with anti-U1-RNP antibodies and Raynaud's phenomenon in SLE patients. *Lupus* 2002;11:35-41.
39. Harper FE, Maricq HR, Turner RE, Lidman RW, LeRoy EC. A prospective study of Raynaud phenomenon and early connective tissue disease. *Am J Med* 1982;72:883-8.
40. Kahaleh B, Matucci-Cerinic M. Raynaud's phenomenon and scleroderma. Disregulation neuroendothelial control of vascular tone. *Arthritis Rheum* 1995;38:1-4.
41. Bollinger A, Fagrell B. Collagen vascular disease and related disorders. In: Bollinger A, Fagrell B, eds. *Clinical capillaroscopy*. Toronto: Hogrefe and Huber, 1990:121-43.
42. Lonzetti LS, Joyal F, Raynaud JP *et al.* Updating the American College of Rheumatology preliminary classification criteria for systemic sclerosis: addition of severe nailfold capillaroscopy abnormalities markedly increases the sensitivity for limited scleroderma. *Arthritis Rheum* 2001;44:735-6.
43. Chen ZY, Silver RM, Ainsworth SK, Dobson RL, Rust P, Maricq HR. Association between fluorescent antinuclear antibodies, capillary patterns, and clinical features in scleroderma spectrum disorders. *Am J Med* 1984;77:812-22.
44. Dick T, Mierau R, Bartz-Bazzanella P *et al.* Coexistence of antitopoisomerase I and anticentromere antibodies in patients with systemic sclerosis. *Ann Rheum Dis* 2002;61:121-7.
45. Okano Y. Antinuclear antibody in systemic sclerosis (scleroderma). *Rheum Dis Clin North Am* 1996;22:709-35.
46. Steen VD, Powell DL, Medsger TA Jr. Clinical correlations and prognosis based on serum autoantibodies in patients with systemic sclerosis. *Arthritis Rheum* 1988;31:196-203.
47. Kuwana M, Kaburaki J, Okano Y, Tojo T, Homma M. Clinical and prognostic associations based on serum antinuclear antibodies in Japanese patients with systemic sclerosis. *Arthritis Rheum* 1994;37:75-83.
48. Weiner ES, Earnshaw WC, Senecal JL, Bordwell B, Johnson P, Rothfield NF. Clinical associations of anticentromere antibodies and antibodies to topoisomerase I. A study of 355 patients. *Arthritis Rheum* 1988;31:378-85.
49. Sato S, Hamaguchi Y, Hasegawa M, Takehara K. Clinical significance of anti-topoisomerase I antibody levels determined by ELISA in systemic sclerosis. *Rheumatology* 2001;40:1135-40.
50. Schachna L, Wigley FM, Morris S, Gelber AC, Rosen A, Casciola-Rosen L. Recognition of Granzyme B-generated autoantigen fragments in scleroderma patients with ischemic digital loss. *Arthritis Rheum* 2002;46:1873-84.
51. Nobili F, Cutolo M, Sulli A *et al.* Impaired quantitative cerebral blood flow in scleroderma patients. *J Neurol Sci* 1997;152:63-71.
52. Sulli A, Savarino V, Cutolo M. Lack of correlation between gastric *Helicobacter pylori* infection and primary or secondary Raynaud's phenomenon in patients with systemic sclerosis. *J Rheumatol* 2000;27:1820-21.
53. Cutolo M, Nobili F, Sulli A *et al.* Evidence of cerebral hypoperfusion in scleroderma patients. *Rheumatology* 2000;39:1366-73.
54. Filaci G, Cutolo M, Basso M *et al.* Long-term treatment of patients affected by systemic sclerosis with cyclosporin A. *Rheumatology* 2001;40:259-60.
55. Distler O, Del Rosso A, Giacomelli R *et al.* Angiogenic and angiostatic factors in systemic sclerosis: increased levels of vascular endothelial growth factor are a feature of the earliest disease stages and are associated with the absence of fingertip ulcers. *Arthritis Res* 2002;4:R11.
56. Cutolo M, Grassi W, Matucci-Cerinic M. Raynaud's phenomenon and capillaroscopy. *Arthritis Rheum* 2003;48:3023-30.